

COMPLETELY IMPACTED TEETH IN DENTATE AND EDENTULOUS JAWS

¹WAFAL-FALEH, BDS, MSC

ABSTRACT

The aim of this study was to study the prevalence of completely impacted teeth in dentate and edentulous jaws. Panoramic radiographs of 2000 patients were retrospectively evaluated. There were 1124 females and 876 males who attended dental clinic at King Saud University. The tooth was considered impacted when it is completely covered with bone or not aligned with the rest of the teeth in either dental arch. 141 (7.1%) patients were found to have either single or multiple completely impacted teeth. It was found more common in dentate patients 7.3% than edentulous 5.3%. 119 (6%) patients had permanent tooth impaction where as 22 patients (1.1%) had supernumerary impaction, most of them were found in male dentate patients. The most common permanent tooth found to be impacted was permanent canine followed by premolar. For supernumerary impaction, supernumerary teeth resemble the morphology of the premolar tooth in the premolar area were more common than mesiodens. Radiographic examination with panoramic radiograph is not enough for examination of the impacted teeth. More detailed examination is needed to evaluate the exact location of the impacted teeth in the dental arch and its proximity to the vital structures or to the adjacent teeth. Therefore, cone beam computed tomography (CBCT) is recommended.

Key words: *Impacted permanent, impacted supernumerary teeth, Dentigerous cyst, Multiple supernumerary teeth.*

INTRODUCTION

Impaction or pathological impaction is defined as failure of a tooth to erupt in its appropriate site in the dental arch within its normal period of growth.^{1,2} A large number of completely impacted teeth may be retained in either jaw without any symptom.³ The impacted tooth could be one of the permanent tooth or a supernumerary tooth. A supernumerary tooth is one that is additional to the normal series and can be found in any region of the dental arch.⁴ The occurrence of supernumerary teeth is a relatively uncommon dental anomaly. Supernumerary teeth have frequently been observed as solitary teeth. The etiology of supernumerary teeth is still remaining unclear. However several theories have been proposed. Multiple supernumerary teeth are rare. Most cases are found in association with syndromes such as Gardner's syndrome, cleidocranial dysostosis and cleft lip and

palate.⁵⁻⁸ It has been reported that the prevalence for non-syndromic multiple supernumerary teeth is less than 1%.^{9,10} The literature reported prevalence of supernumerary teeth within the mandible and maxilla varies from 0.2-0.9%.¹¹ Mesiodens is considered the most common supernumerary teeth with reported incidence of 0.15 to 1.9% and has a slight male predominance. Any permanent tooth in the dental arch can be impacted, but the teeth most frequently involved in a descending order are the mandibular and maxillary third molars, the maxillary canines, the mandibular and maxillary second premolar, and maxillary central incisors.¹² Therefore, the aim of this research was to study the prevalence of completely impacted teeth in dentate and edentulous jaws.

METHODOLOGY

This is a retrospective study based on 2000 panoramic radiographs of adult individuals. The panoramic

¹ Assistant Professor, Department of Oral Medicine and Diagnostic Oral Science, Division of Oromaxillofacial Radiology, College of Dentistry King Saud University, Riyadh.

Correspondence: P.O Box 5967, Riyadh 11432, Kingdom of Saudi Arabia. Phone: + 966 505225648 (Cell) E.mail. wafaalfaleh@hotmail.com

radiographs were chosen randomly from active dental record at the college of dentistry, King Saud University. All of the panoramic radiographs were made using one of two different panoramic machine (orthopantomograph 10 machine (Siemens, Germany) or orthopantomaograph –OP 100; instrumentarium, Finland with exposure parameters of 57-90 KVP, 2-16 mA, and equivalent filtration of 2.5 mm Al, using Kodak Lanex regular intensifying screen and Kodak T-MAT G/RA). The films were processed using HP processor according to manufacturer instructions. The panoramic radiographs were originally made for various dental purposes and not for this study. Thus, no attempt was made to pre-select the panoramic radiograph. All panoramic radiographs were evaluated by the author. The tooth was considered impacted when it is completely covered with bone or not aligned with the rest of the teeth in either dental arch or certain pathological condition that prevent tooth from eruption such as dentigerous cyst or odontoma. Patients recorded and panoramic radiographs were evaluated and the following data were recorded: age, sex, number of impacted teeth and the type (permanent or supernumerary) of tooth is recorded as well as their location and pathologies associated with impaction. Third molar impactions were excluded because in some cases the tooth might be impacted and removed surgically outside the dental college which can not be confirmed, therefore it is not considered in this study. The evaluation was

performed under standard conditions of radiographic interpretation such as viewing box and dim room lighting.

Data analysis was performed using statistical Package for the Social Sciences SPSS software program. Gender, mean age and dental status were analyzed. Significant differences between the dentate and edentulous patients were analyzed as well as the difference between males and females with respect to type of impaction using Pearson’s Chi-square test. The level of statistical significance was set at 5%. The research project was approved by the College of Dentistry Research Center (CDRC) King Saud University.

RESULTS

The study sample comprised of 2000 panoramic radiographs which belongs to 1124 female (56.2%) with mean age of 37 years (SD 15.5) and 876 male (43.8%) with mean age of 39.7 (SD 15.9). The age of the total sample ranged from 15-90 years.

There were 1737 dentate (86.9%) with mean age of 35 years (SD 13.7) and 263 (13.2%) edentulous patients with mean age of 60 years (SD 9.6).

One hundred forty one (7.1%) patients out of 2000 were found to have either single or multiple completely impacted teeth of either type, these impacted teeth were found in 127 dentate and 14 edentulous patients,

TABLE 1: DISTRIBUTION OF IMPACTION TYPE BY DENTAL STATUS

Dental Status	Type of Impaction		
	Impacted teeth	Supernumerary	Permanent teeth
Dentate	127 (7.3%)	22 (17.3%)	105 (82.7%)
Edentulous	14 (5.3%)	0 (0%)	14 (11.8%)
Total	141 (7.1%)	22 (17.3)	119 (84.4%)

Percentages within dental status

TABLE 2: THE DISTRIBUTION OF IMPACTIONS BY TOOTH TYPE AND GENDER

Gender	Tooth Type					Total
	Canine	Premolar	Central	Canine & central	Canine & premolar	
Male	36 (85.7%)	3 (7.1%)	1 (2.4%)	0	2 (4.8%)	42 (100%)
Female	58 (74.4%)	15 (19.2%)	1 (1.3%)	2 (2.6%)	2 (2.6%)	78 (100%)
Total	94 (78.3%)	18 (15.0%)	2 (1.7%)	2 (1.7%)	4 (3.3%)	120 (100%)

Percentages within gender

TABLE 3: THE FREQUENCY OF VARIOUS TYPE OF SUPERNUMERARY IMPACTED TEETH BY GENDER.

Gender	Type of Supernumerary Impaction			
	Premolar morphology	Mesiodens	Distomolar	Total
Male	11(64.7%)	59(29.4%)	1(5.9%)	17(100%)
Female	3(60.0%)	2(40.0%)	0	5(100%)
Total	14(63.6%)	7(31.8%)	1(4.5%)	22(100)

Percentage within gender

although no significant differences were found between them with p value 0.24. Table (1) demonstrates the frequency, percentage and type of impacted teeth in dentate and edentulous patients.

Figure 1 showed impacted permanent teeth in dentate patients.

The Impacted teeth were found more commonly in female than in male. They were 83 (7.4%) and 58(6.6%) female and male patients respectively, however, no significant difference were found between them using Pearson’s Chi-square test with P value 0.43. The most common tooth found to be impacted were permanent canines where they were found in 94 patients (4.7%) followed by premolars where they were found in 18 patients (0.9%) and to less frequently central incisors (0.1%). None of the patients had impaction of the first or second molar. Table (2) demonstrates the number and prevalence of various types of permanent teeth impactions in male and female patients.

Permanent tooth/teeth impactions were found more commonly than supernumerary teeth. It was found In 119 patients (6%) while the supernumerary impactions were recorded in 22 dentate patients (1.1%). Total of 35 supernumerary impacted teeth were recorded in 22 dentate patients, more in males than females. Table 3 shows the frequency of various types of supernumerary teeth impaction in male and female dentate patients.

None of the supernumerary impacted teeth were found in edentulous patients. Supernumerary impacted teeth were found more commonly in males (29.3%) than in female (6%) with slight significant difference between them with P value 0.02. Supernumerary impacted tooth that resemble the morphology of the premolar tooth in the premolar area were more common than mesiodens in the anterior area where it

had been recorded as 0.7 percent and 0.4 percent for the premolar morphology and mesiodens respectively. The recorded impacted mesiodens was single in all of the seven patients with various pattern of impaction have

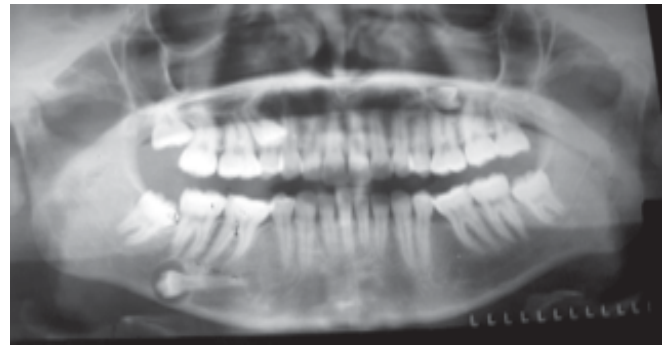


Fig 1: A panoramic radiograph of 20 year female patient shows multiple impacted permanent teeth # 15, 25 and 45 with dentigerous cyst formed around the crown of tooth # 45 leading to thinning of the inferior border of the mandible.

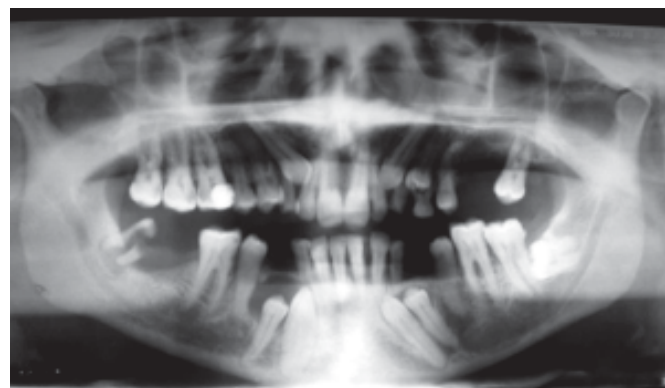


Fig 2: A panoramic radiograph of 45 years male patient shows multiple impacted permanent teeth number 13, 23, 24, 33, 34, 43 and 44 with well defined unilocular radiolucency surrounding the crown on impacted teeth # 43 and 44.

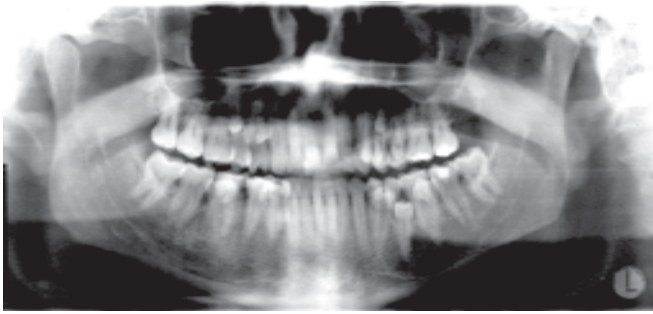


Fig 3: A panoramic radiograph of 34 year male patient shows non-syndrome multiple impacted supernumerary teeth of both upper and lower jaws in the premolar area of four quadrants without any complication to the adjacent teeth.

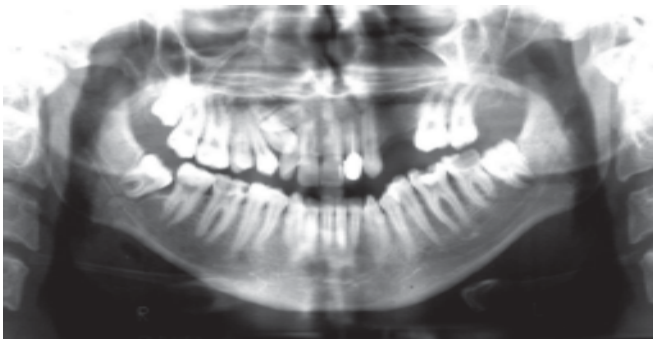


Fig 4: A panoramic radiograph of 40 year old male shows impacted canine # 13 and supernumerary tooth in the maxillary arch apical to the central and lateral teeth that may cause impaction of the permanent canine

been demonstrated, where as impacted supernumerary tooth with premolar morphology recorded either single or multiple through out the dental arches. Multiple supernumerary impacted teeth more than five teeth was uncommon in this study, the prevalence was 0.1%, only one case had been found with ten impacted supernumerary teeth in the premolar area. Figure 3 show a panoramic radiograph of 34 year male patient with multiple impacted teeth with out history of any syndrome.

None of the supernumerary teeth demonstrated cystic transformation. Displacement and resorption of the adjacent teeth was not evident. Where as cystic formation observed with some cases of permanent tooth impaction. (Figures 1 & 2). Multiple permanent teeth impaction was found less frequently than single tooth impaction. Figure 3 shows a panoramic radiograph of 45 year male patient had multiple impactions with seven permanent teeth being impacted with no

history of any systemic diseases or known syndrome. One case was found where the patient had impacted supernumerary and permanent teeth at the same time.(figure 4)

DISCUSSION

Impacted tooth remain embedded in the jaw bone for various reasons, the most common cause of impaction of permanent teeth are crowding of the teeth that lead to no room for the tooth to erupt in the jaw at the appropriate time. Teeth may also become displaced in the jaw due to unknown causes resulting in impaction of the tooth. Many impacted teeth may cause no problem for people and may never be aware of this problem unless radiographic examination performed for the patients when they start to seek dental treatment. Whereas, some impaction may cause serious complication therefore early discovery of this impacted teeth may prevent such complication.

In this study permanent tooth impaction found more commonly than supernumerary teeth, as well as impacted teeth more common in dentate patients and this finding is compatible with other^{3,13} findings. Despite the fact that in some edentulous patients, it was difficult to know if the impacted teeth especially in the premolar area are permanent or supernumerary, therefore all the impacted teeth in the edentulous patients were considered permanent because no previous panoramic radiographs were available for comparison. The result of this study showed that permanent canine is the most common tooth found to be impacted followed by lower premolar and less frequently central teeth, this is the same finding reported in the literature¹.

Supernumerary teeth mean extra teeth, their shape and size may resemble the group of teeth at the site where they are found in the jaws or there may be little or no resemblance at all⁷. They may occur impacted or erupted, singly or multiple, unilateral or bilateral and in one or both jaws. The prevalence of supernumerary teeth in a population ranging from 0.1 percent to 3.6 percent^{14,15}, the result of this study showed that the prevalence of supernumerary teeth impaction fall within this range. For mesiodens, in 7 patients the tooth was single, while the supernumerary teeth resembled the premolar morphology were found in 14 patients either single or multiple.

In several studies^{9,10} where eruption of the supernumerary teeth in the permanent dentition was evaluated, around 25% of the supernumerary teeth were erupted while the rest were impacted. In this study all of the supernumerary tooth/teeth recorded were impacted without any associated dental anomalies.

Several researchers^{16,17} reported that mesiodens is the most common supernumerary tooth in the premaxilla between the two central incisors; it could resemble the morphology of the permanent teeth or has unusual morphology. The direction of the crown of the mesiodens may be normal, inverted or horizontal. The result of this study did not support their findings where supernumerary tooth/teeth that resemble premolar morphology recorded more commonly than the mesiodens however, supernumerary teeth found more commonly in male patients than female patients, which is the same finding reported by Acikgoz et al¹³.

Multiple impacted supernumerary teeth are not common occurrence, although a single or a few supernumerary tooth/teeth in each case have been widely reported in the literature^{18,19}. Yuosf⁷ in 1990 reviewed many cases reported in the English literature from 1969 to 1990, he reported a predilection of non-syndrome multiple supernumerary teeth to occur in the mandible at the premolar area, which is the same finding reported in this study, since there was one case belong to male patient with no history of any systemic disease or known syndrome with multiple impacted supernumerary teeth that resemble premolar morphology found in the premolar area of both arch.

Dentigerous cyst formed around supernumerary teeth account for 5% of all dentigerous cysts formed around impacted tooth. It has been reported in the literature^{19,20} that most of the cyst formed around a mesiodens in the anterior maxilla, however none of the supernumerary teeth in this study demonstrated cystic transformation, as well as displacement and resorption of the adjacent teeth were not evident. This finding is in agreement with Acikgoz et al¹³ therefore, close follow up of the patients with impacted supernumerary as well as with permanent teeth is required to prevent further complication formed by cystic transformation or resorption of the adjacent teeth root.

There was one case where the patient had impacted canine and supernumerary teeth in the anterior

maxilla. The presence of the supernumerary tooth could be the cause of the impaction of the permanent canine. Early diagnosis of impacted supernumerary tooth and treatment by extraction of the supernumerary tooth may prevent such complication.

In this study the radiographic examination was carried out with panoramic radiograph as screening for the patients seeking dental treatment. From the findings reported in this study it seems that panoramic radiograph is considered good for detection of impaction. If detailed examination is needed to evaluate the exact location of the impacted teeth in the dental arch and it's proximity to the vital structures or the adjacent teeth in either dental arches panoramic radiograph is not enough. Therefore, cone beam computed tomography (CBCT) is recommended for more detailed examination. CBCT has many advantages over simple panoramic film such as accurate visualization of head and neck structures. The compact size and relatively low radiation dosage as well as the short scanning time with CBCT scanner make it suitable for imaging the craniofacial region, including dental structures²¹.

CONCLUSIONS

- Most of the impacted teeth were diagnosed coincidentally during radiographic examination.
- Permanent tooth impaction is more common than supernumerary tooth.
- Complication like cystic transformation resulting from impaction more common with permanent teeth impaction.
- Extraction of the asymptomatic supernumerary impacted teeth is not recommended unless complication is present.
- Follow up of the patients with impacted teeth through periodic radiographic examination.
- CBCT is recommended for detailed examination.

REFERENCES

- 1 Grover PS, Lorton L. The incidence of unerupted permanent teeth and related clinical cases. *Oral Surg. Oral Med. Oral Pathol* 1985; 59:420-425.
- 2 Kufteinec MM, Shapira Y. The impacted maxillary canine. I. Review of concepts. *J Dent Child* 1995; 62: 317-24.

- 3 Yamaoka M, Furusawa K, Fujimoto K, Uematsu T. Completely impacted teeth in dentate and edentulous jaws. *Australian dent J* 1996; 41: (3): 169-72.
- 4 Garvey MT, Barry HJ, Blake AM. Supernumerary teeth- An overview of classification, diagnosis and Management. *J Can Dent Assoc* 1999; 65:612-6.
- 5 Golan I, Baumert U, Hrala BP, Mubig D. Early craniofacial signs of cleidocranial dysplasia. *Int J Paediatr Dent* 2004; 14:49-53.
- 6 Atasu M, Dumlu A, Ozbayrak S. Multiple supernumerary teeth in association with cleidocranial dysplasia. *J Clin Pediatr Dent* 1996; 21: 85-91.
- 7 Yusof WZ. Non-syndrome multiple supernumerary teeth. literature review. *J Can Dent Assoc* 1990; 56: 147-149.
- 8 Hattab FN, Yasin OM, Rawashdeh MA. Supernumerary teeth: report of three cases and review of the literature. *J Dent Child* 1994; 61: 382-393.
- 9 Manrique Mora MC, Bolanos Carmona MV, Briones Lujan MT. Molarization and development of multiple supernumerary teeth in the premolar region. *J Dent Child* 2004; 71: 171-174.
- 10 Rajab LD, Hamdan MAM. Supernumerary teeth: review of the literature and survey of 152 cases. *Int J Pediatr Dent* 2002; 12: 244-254.
- 11 Saini T, Keene JJ, Whetten J. Radiographic diagnosis of supernumerary premolars: case review. *ASDC J Dent Child* 2002 May-Aug;69(2):184-90, 125
- 12 Moyers RE. *Handbook of orthodontics*. Chicago: Year Book Medical, 4th Ed 1988: pp 140. 387.
- 13 Acikgoz A, Acikgoz G, Tunga U and Otan F. Characteristic and prevalence of none-syndrome multiple supernumerary teeth: a retrospective study. *DentomaxilloFac Radiol* 2006; 35: 185-190.
- 14 Pindborg, J.J. *Pathology of dental hard tissues*. Philadelphia, W.B. Saunders Co, 1970.
- 15 Schulze C . Incidence of supernumerary teeth. *Dent Abstr* 1961 6:23.
- 16 Von Arx T. Anterior maxillary supernumerary teeth – A clinical and radiographic study. *Aust Dent J* 1992; 37: 189-95.
- 17 Asaumi J I, shibata Y, Yanagi Y et al. Radiographic examination of mesiodens and their associated complication. *DentomaxilloFac Radiol* 2004; 33:125-7.
- 18 Ruprech A. Batniji S. and El-Newelhi E. Incidence of supernumerary teeth. *Ann Dent* 1984;43:18-21.
- 19 Spouge JD. *Oral pathology*. St.Louis, C.V. Mosby Co, 1973. Lustmann J, Bodner L. Dentigerous cyst associated with supernumerary teeth. *Int Oral MaxilloFac Surg* 1988; 17: 100-2.
- 20 Dinkar AD, Dawasaz AA and Shenoy S. Dentigerous cyst associated with multiple mesiodens: a case report. *J Indian Soc Pedod Prev Dent* 2007; mach 25(1):56-9.
- 21 White SC and Pharaoh MJ. In white & pharaoh 6th ed. *Oral radiology: principles and interpretation*. Mosby ; 2009, ch 14 pp 225.