

# PREVALENCE OF IMPACTED AND ECTOPIC TEETH IN PATIENTS SEEN IN A TERTIARY CARE CENTRE

<sup>1</sup>ROZINA NAZIR, <sup>2</sup>ERUM AMIN, <sup>3</sup>HAMEED ULLAH JAN

## ABSTRACT

*The objective of the study was to calculate the prevalence of most frequent impacted and, ectopic teeth in patients reporting to Orthodontic OPD at Armed Forces Institute of Dentistry (AFID) Rawalpindi. Duration of the study was one year from 7 December 04 to 6 December 05.*

*The sample consisted of 388 females and 162 males. Complete record of the patient was taken. 500 patients of both sexes of age 8-25 years were fully analyzed, 124 patients had impacted teeth and 102 patients had ectopic teeth. Most frequently impacted teeth were third molars especially lower right ones. Most frequent ectopic teeth were canines especially upper left canines.*

*Comparing the two jaws, impaction was more common in the mandible 52(10.4%) than in maxilla 30(6%), while 42(8.4%) patients had impacted teeth in both jaws simultaneously. Only one patient had 5 teeth impacted. Most commonly ectopic teeth were maxillary canines which were 102 (60.5%). Ectopic teeth were more common in females than in males and were more in the upper jaw than in the lower.*

**Key words:** *Impacted teeth, ectopic teeth, mandibular third molar, malposition.*

## INTRODUCTION

A tooth which is completely or partially unerupted and is positioned against another tooth, bone, or soft tissue so that its further eruption is unlikely is called impacted tooth.<sup>1</sup> In impacted teeth, root development might have finished, but unaided eruption is not expected to occur.<sup>2</sup> Occasionally, malposition of a permanent tooth bud can lead to eruption at a wrong place. This condition is called an ectopic eruption and the tooth is called ectopic tooth.<sup>3</sup>

Although there are some hereditary patterns leading to impacted teeth, the etiologic factors of most probable concern are malposed tooth germs, prolonged retention of primary teeth, localized pathologic lesions, and shortening of arch length.<sup>4</sup> Ectopic eruption of maxillary first molars is associated with large primary and permanent teeth, a diminished maxillary length, posterior positioning of maxilla, and an atypical angle of eruption of the first molar.<sup>4</sup>

Any tooth can be impacted but the teeth most frequently involved are the mandibular third molars, maxillary cuspids, maxillary third molars, mandibular and maxillary second bicuspid and maxillary central incisors, in that order. Most common teeth found in ectopy are maxillary first permanent molars, maxillary cuspid followed by mandibular cuspid, maxillary second premolar, and maxillary lateral incisors. About one half of all the tooth germs in ectopy, other than first molars, are maxillary cuspids and two third of all the ectopic cuspids are found in girls.<sup>3</sup>

Impaction is diagnosed most frequently and easily when a tooth is long delayed in erupting, yet an extra

effort should be made to make a diagnosis at an earlier date.<sup>3</sup> Impaction is suspected clinically when opposing tooth is erupted and is almost certain when the same tooth of the opposite side is present.<sup>5</sup> Palpation of the buccal and palatal mucosa, using the index finger of both the hands simultaneously is recommended to assess the bulge and position of erupting maxillary canines.<sup>6</sup>

Impacted and ectopic teeth may lead to spacing in the arch & shifting of the midline if contralateral tooth is erupted. Maxillary incisors resorption due to ectopically positioned permanent canine can be silent, and devastating.<sup>7</sup> They can cause migration of the neighboring teeth and loss of arch length; internal resorption; dentigerous cyst formation; external root resorption of the neighboring teeth; infection particularly with partial eruption; and referred confusing pain.<sup>8</sup>

After conducting this study we will be able in a better position to determine the quantum of patients presented with impacted or ectopic teeth. It will also help us in getting clue so as to make comparison with other studies being conducted on various population groups. We will thus extract a native frequency of impaction and ectopia in our own population. This data will then be used for future reference and comparison by other researchers not only Pakistan but also by other countries.

## METHODOLOGY

Descriptive study was conducted in Orthodontics out patient department at the Armed Forces Institute of Dentistry (AFID) Rawalpindi, from 7 December 2004 to 6 December 2005. Five hundred patients were

<sup>1,2</sup> Residents FCPS –II Orthodontics

<sup>3</sup> Assoc Prof of Orthodontics, Head 28 Military Dental Centre, Lahore Cantt, Email: [huj100@hotmail.com](mailto:huj100@hotmail.com)

selected from out patient department. Orthopantomogram and photographs were taken. The sample consisted of 388 females 162 males. We took this sample of 500 patients because our study duration was comprised of only one year. Purposive sampling was used and an informed consent was taken from patients. Patients selected were between ages 8 to 25 years. All Patients were having class I, II or III molar relationship. Patients having different dental classifications on both sides were also included in the study. Any patient giving history of extractions of impacted teeth was ruled out. Patients with any major dentofacial abnormalities like cleft lip and palate; with any obvious dental pathology e.g. cysts, granuloma etc, primary dentition, or patients having supernumerary/supplemental teeth were excluded from the study.

Demographic data was collected as case number, date of report, name, age and gender of the patient on separate history sheets. History included the recording of missing teeth, extractions of teeth, ectopic teeth, extractions related to orthodontic treatment, accident involving facial area; about artificial prosthesis. Total of 500 patients were thoroughly evaluated. Patients having age range from 8 to 25 years were taken and divided into four age groups as 8 to 12, 13 to 16, 17 to 20, and 21 to 25. Orthopantomographs of all 500 patients of both the genders were thoroughly analyzed. The snapshots were made at the radiology department of Armed Forces Institute of Dentistry by using more versatile "Rotograph plus" apparatus. While taking snapshots, the time of the exposition was 65 Kv/15 MAS for OPG and 55Kv/ 05-08MAS for occlusal view. The snapshots were made on films Agfa. The analysis of the snapshots and determination of impacted and ectopic teeth for each patient were pursued in the same institute. All relevant data was collected on a specified Proforma.

Data collected was entered into SPSS version 10. Pie chart for proportions of age groups, gender, mean and standard deviation of ages were calculated. Frequency was determined for number of impacted and ectopic teeth in both male and female population, as well as in maxilla and mandible.

## RESULTS

In our study based on a set of 500 orthopantomograms of patients from age 18-25 years (Fig 1) selected by the method of random choice, 162(32.4%) were males and 388(67.6%) were females (Fig 2).

Out of 162 males, 12(7.40%) had a single impacted tooth while 21(12.96%) males had two impacted teeth. There were three impacted teeth in 6(3.70%) males, while four impacted teeth in 4(2.47%) males. Only one patient (0.62%) had a uniqueness of five impacted teeth. Maximum impacted teeth in male patients were 3<sup>rd</sup> molars especially lower right third molar.

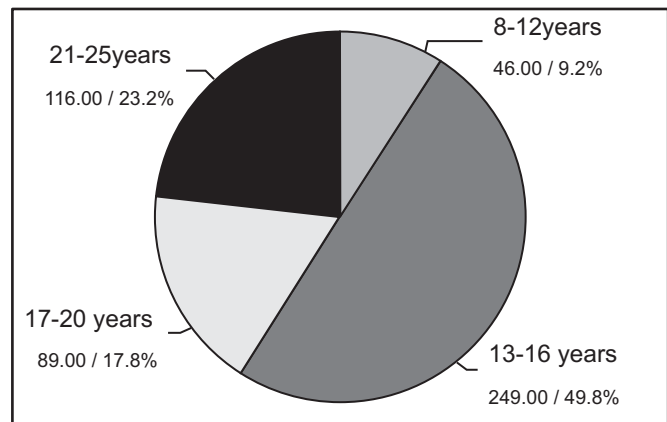


Fig 1: Age/distribution of the patients

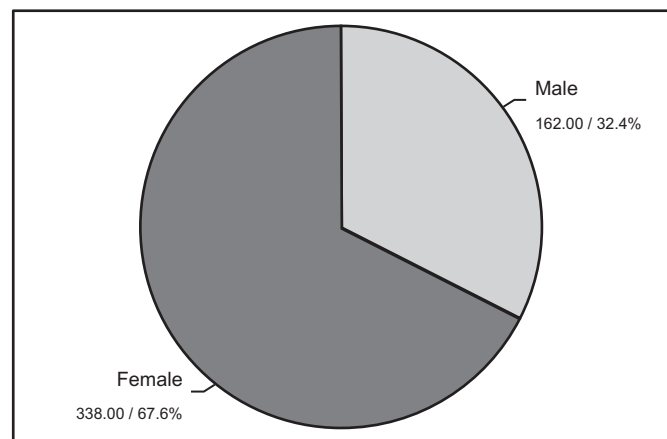


Fig 2: Gender distribution of the patients

In 388 females, 23(5.93%) had single impacted tooth, 25(6.44%) had two impacted teeth, 10(2.58%) had three impacted teeth, and 21(5.41%) had four impacted teeth. In male patients total frequency of impacted teeth was 44(27.16%) while in female it was 129(33.24%).

Out of all total patients, 74(14.8%) patients had lower right 3<sup>rd</sup> molar impacted which was the most frequently impacted tooth followed by lower left third molar in 69(13.8%) of patients. Upper right canine was the second most impacted tooth in 21 patients (4.2%) and was more prevalent in females<sup>13</sup> as compared to male members.<sup>8</sup>

Thirty (6%) patients had impacted teeth in the maxilla, fifty two (10.4%) had in the mandible, while forty two (8.4%) patients had impacted teeth both in the upper and lower jaw.

Out of 162 males, 122 (75.30%) were without any ectopic teeth, 17(10.49%) had 1 ectopic tooth, 8 (4.93%) had 2, 6(3.70%) had 3, 5 (3.08%) had 4, 1(0.61%) had 5, 2(1.23%) had 6 and 1(0.61%) had only 8 ectopic teeth. Out of 388 females 278 had no ectopic teeth, 23 had one, 19 had 2, 5 had 3, 8 had 4, 1 had 5 while another 1 had 6, 2 had 7 and only one patient had 8 ectopic teeth.

Maximum number of ectopically placed tooth was upper right canine which was 53(10.6%), Teeth ectopic in the maxilla and mandible were 30. 56 teeth in total were ectopic only in the maxilla while 15 were in the mandible.

## DISCUSSION

The use of dental panoramic tomography (DPT) for study of impacted teeth is limited to hospital dental patients and large dental practices because of associated costs and ethical considerations.<sup>9-20</sup>

To ensure our diagnostic validity of the study we thoroughly examined all patients and their radiographic findings. Although this study may not represent the Pakistani population as a whole, the results are fruitful for primary health workers as the patients studied represent the wide range of dental patients reporting to our setup. The prevalence of impacted teeth in the studied population was relatively high as compared to other studies; this high ratio is self evident from the sample selected which was solely from orthodontic OPD of AFID.

During collection of clinical data, OPG was extensively used for the identification of the diagnostic parameters, specified in this study,<sup>21-22</sup> but unfortunately due to shortcoming of OPG due to considerable distortion in the frontal portion of the dentoalveolar complex, periapical radiographs were required for additive verification.

We divided the sample into 4 age groups just for convenience. The major age group ranged between 13-16 years with a total number of 249 (49.8%) patients, out of which 43 had impacted while 62 had ectopic teeth. The reason for high prevalence in this age group may be that most of these teenagers are eager to report this problem to orthodontists just for esthetic reasons.

The frequency and the type of tooth impacted was compatible with the previous reports.<sup>9,10,16,17</sup> with most common being third molars, followed by upper canines. This predilection for impaction of lower third molars has not been reported in studies of other ethnic groups.

Among 500 patients 173 patients had impacted teeth. Out of 308 impacted teeth mandibular third molars were the most commonly [143(46.42%)] impacted teeth followed by maxillary third molars [70(22.72%)]. As far as the developmental stages and eruptive status of impacted third molars is concerned, its distribution was almost similar between the left and right sides of the patients.

In a study conducted by Rayne J and Bass TB permanent maxillary canines were the second most frequently impacted teeth, the prevalence of their impaction was 1-2% in the general population.<sup>23</sup> Another study conducted by Shah RM showed that the maxillary canine is second only to the mandibular third molars in the frequency of impaction, with the rate that

varies from less than 0.8% to 2.8%.<sup>16</sup> Dachi and Howell<sup>10</sup> pointed out that this condition is more than twice as common in girls as in boys.

In our study maxillary canines 38(12.33%) were the second most impacted teeth which coincided with the study of Rayne J and Bass TB. In another study the prevalence of impacted maxillary canines was 0.9–2.2%<sup>10,24,25</sup> which was much less than our study, this might be due to our patients who solely picked up from orthodontic OPD. Impacted maxillary canines, like ours, are three times as common in girls as in boys.<sup>26,27</sup> The literature is replete with the tooth impaction which is a more frequent phenomenon.<sup>9-19</sup> However there is considerable variation in the prevalence and distribution of impacted teeth in different regions of the jaws.<sup>10-19</sup> Affecting factors include; selected age group, timing of dental eruption, and the radiographic criteria for dental development and eruption

After the third molars and maxillary canines, the most commonly impacted tooth was the mandibular second premolar, having incidence of impaction from 2.1% to 2.7%.<sup>28</sup> This was in accordance with our study, where mandibular second premolar 14(4.54%) was third in ranking of impaction. Regarding ectopy, the most frequently found ectopic teeth were the maxillary first permanent molars and canines, followed by the mandibular canines, mandibular second premolars, & maxillary lateral incisors.<sup>29</sup> For first permanent maxillary molar the diagnosis is usually made by a routine radiographic examination before the eruption of these teeth, usually between five and seven years of age<sup>30</sup>.

Ectopic eruption of the maxillary first molars showed a variable prevalence that ranged between 2% to 6% as per the population studied.<sup>31</sup> According to Moyers<sup>4</sup> 3% of American children present this type of dental anomaly. Studies conducted by Cheyne Wessels<sup>32</sup> in 1947, revealed that one out of 50 children was affected, being more frequent in males and in upper jaw. Young<sup>33</sup> observed that it affected 3% of a group of 1619 boys and girls while Chintakanon and Boonpinon<sup>34</sup> found a prevalence of 0.75% only.

In our local study the incidence of ectopically erupting maxillary canines was 20.9% which seems somewhat higher as compared to other studies<sup>10,24</sup> this again might be due to our selection criteria of patients already stated. Ectopic canines were found palatally more than buccally with over double the frequency.<sup>21</sup> The etiology of the palatal canine ectopia remains unclear but is likely to be polygenic and multifactorial.<sup>35</sup> In the previous studies, ectopically erupting canines were more frequently seen in girls than in boys.<sup>10,36</sup> Same was the situation in our study, girls were having more ectopically erupting teeth than boys.

Practitioner should become suspicious of the possibility of canine ectopia if the canine is not palpable in

the buccal sulcus by the age of 10-11 years of age or if palpation indicates an asymmetrical eruption pattern. Radiographic procedures prior to the age of 10-11 years are usually of little benefit in terms of the knowledge gained.<sup>37</sup> This clinical examination usually involves taking two radiographs and the use of principle of horizontal or vertical<sup>38</sup> parallax procedure. However the horizontal parallax techniques are more definite than vertical parallax technique in localizing the unerupted tooth.<sup>39</sup>

The limitation of this study was the limited age group. Future studies should be conducted with ages from 5-25 years to find out the ectopia of maxillary first permanent molars.

## CONCLUSION

Ectopic or Impacted teeth send an alarming signal in Pakistan, both for the patient, parents and the treating orthodontist alike. This great concern of ectopia accentuate the importance of an early diagnosis, timely orthodontic management, and customized strategic approach so as to attain the real goal of functional occlusion and dentofacial esthetics at zenith level of dental profession.

## REFERENCES

- 1 Archer WH .Oral and Maxillofacial Surgery. 5<sup>th</sup> ed. Philadelphia: W B Saunders, 1975.
- 2 Becker A, Chaushu S. Success rate and duration of orthodontic treatment for adult patients with palatally impacted maxillary canines. *Am J Orthod Dentofacial Orthop* 2003; 124: 509-14.
- 3 Profit WR. Contemporary Orthodontics. 3<sup>rd</sup> ed. St.Louis: Mosby, 2000.
- 4 Moyer RE .Hand book of orthodontic. 4<sup>th</sup> ed. Chicago: Year Book Medical Publishers, 1988.
- 5 Pederson G W .Oral surgery. Philadelphia: W B Saunder, 1988.
- 6 Khan N. Clinical and radiological evaluation of maxillary canine after autotransplantation [dissertation]. Karachi: College of physicians & surgeons Pakistan, 2003.
- 7 Otto RA. Early and unusual incisor resorption due to impacted maxillary canines. *Am J Orthod Dentofacial Orthop* 2003; 124:446-9.
- 8 Shafer WG, Hine MK, Levy BM.A text book of oral pathology. 4<sup>th</sup> ed. Philadelphia: W B Saunders, 1984.
- 9 Ahlqwist M, Grondahl HG. Prevalence of impacted teeth and associated pathology in middle-aged and older Swedish women. *Community Dent Oral Epidemiology* 1991; 19:116-9.
- 10 Dachi SF, Howell FV. A survey of 3874 routine full-mouth radiographs: A study of impacted teeth. *J Oral Maxillofac Surg* 1961; 14:1165-9.
- 11 Eliasson S, Heimdahl A, Nordenram A. Pathological changes related to long-term impaction of third molars. A radiographic study. *Int J Oral Maxillofac Surg* 1989; 18:210-2.
- 12 Haidar Z, Shalhoub SY. The incidence of impacted wisdom teeth in a Saudi community. *Int J Oral Maxillofac Surg* 1986; 15:569-71.
- 13 Hattab FN, Rawashdeh MA, Fahmy MS. Impaction status of third molars in Jordanian students. *Oral Surg Oral Med Oral Pathol Oral Radiol Endod* 1995; 79:24-9.
- 14 Hugoson A, Kugelberg CF. The prevalence of third molars in a Swedish population. An epidemiological study. *Community Dent Health* 1988; 5: 121-38.
- 15 Peltola JS. A Panoramatomographic study of the teeth and jaws of Finnish University students. *Community Dent Oral Epidemiology* 1993; 21: 36-9.
- 16 Sandhu SS, Kapila BK. Incidence of impacted third molars. *J Indian Dent Assoc* 1982; 54: 441-4.
- 17 Stermer Beyer-Olsen EM, Bjertness E, Eriksen H, Hansen BF. Comparison of oral radiographic findings among 35-year-old Oslo citizens in 1973 and 1984. *Community Dent Oral Epidemiol* 1989; 17: 68-70.
- 18 Yamaoka M, Furusawa K, Yamamoto M. Influence of adjacent teeth on impacted third molars in the upper and lower jaws. *Aust Dent J* 1995; 40: 233-5.
- 19 Nitzan D, Keren T, Marmary T. Does an impacted tooth cause root resorption of the adjacent one? *Oral Surg Oral Med Oral Pathol* 1981; 51: 221-4.
- 20 Kahl B, Gerlach KI, Hilgers RD. A long term follow-up, radiographic evaluation of asymptomatic impacted third molars in orthodontically treated patients. *Int J Oral Maxillofac Surg* 1994; 23: 279-85.
- 21 Ericson S, Kurol J. Radiographic examination of ectopically erupting maxillary canine. *Am J Orthod Dentofacial Orthop* 1987; 91: 483-92.
- 22 Lindaurer SJ, Rubenstein LK, Hang WM, Clark Andersen W, Isaacson RJ. Canine impaction identified early with panoramic radiographs. *J AM Dent Assoc* 1992; 123: 91-7.
- 23 Rayne J. The unerupted maxillary canine. *Dent Pract Dent Rec* 1969; 19: 194-204.
- 24 Thilander B, Myrberg N. The prevalence of malocclusion in Swedish schoolchildren. *Scand J Dent Res.* 1973; 81: 12-20.
- 25 Ericson S, Kurol J. Radiographic assessment of maxillary canine eruption in children with clinical signs of eruption disturbance. *Eur J Orthod* 1986; 8:133-40.
- 26 Ericson S, Kurol J. Resorption of incisors after ectopic eruption of maxillary canines. A CT study. *Angle Orthod* 2000; 70: 415-23.
- 27 Ericson S, Kurol J. Resorption of maxillary lateral incisors caused by ectopic eruption of the canines. An analysis of predisposing factors. *Am J Orthod Dentofacial Orthop* 1988; 94: 503-13.
- 28 Oikarinen VJ, Julku M. Impacted premolars: an analysis of 10,000 orthopantomograms. *Proc Finn Dent Soc.* 1974; 70: 95-8.
- 29 Wei SH. Pediatric Dentistry: Total patient care. 1<sup>st</sup> ed. Philadelphia, Pa: Lea and Febiger. 1988; 462-63.
- 30 O'Meara WF. Ectopic eruption pattern in selected permanent teeth. *J Dent Res.* 1962; 41: 607-16.
- 31 Kimmel NA, Gellin ME , Bohannon H, Kaplan AL. Ectopic eruption of maxillary first permanent molars in different areas of the United States. *J Dent Child* 1982; 4: 294-96.
- 32 Cheyne YD, Wessels KE. Impaction of first permanent molar with resorption and space loss in region of second deciduous molar. *J Am Dent Assoc* 1947; 35: 774-876.
- 33 Young DH. Ectopic eruption of first permanent molar. *J Dent child.* 1957; 24: 153-62.
- 34 Chintakanon K, Boonpinon P. Ectopic eruption of first permanent molars: prevalence and etiological factors. *Angle Orthod* 1998; 68: 153-60.
- 35 Peck S, Peck L, Kataja M. Concomitant occurrence of canine malposition and tooth agenesis: evidence of orofacial genetic fields. *Am J Orthod Dentofacial Orthop* 2002; 122: 657-60.
- 36 Isaason KG, Thom AR. Orthodontic Radiographs guidelines. 2<sup>nd</sup> ed. Br Orthod Soci 2001.
- 37 Mason C, Papadakou, Roberts GJ. The radiographic localization of impacted maxillary canines: a comparison of methods. *Eur J Orthod* 2001, 23: 25-34.
- 38 Southall PJ, Gravely JF. Vertical parallax radiology to localize an object in the anterior part of the maxilla. *Br J Orthod* 1989; 16: 79-83.
- 39 Armstrong C, Johnston C, Burden D, Stevenson M. Localizing ectopic maxillary canines- horizontal and vertical parallax? *Eur J Orthod* 2003; 25: 585-89.