

INTRAORAL MAXILLARY MOLAR DISTALIZATION: A REVIEW

¹LUBNA F. AL-FALEH

SUMMARY

Distalization of maxillary molars with intraoral appliance is a non-extraction treatment approach for correction of Class II malocclusion that have been described as an alternative to Head gear, since non-extraction approach in correcting class II malocclusion is gaining a lot of attention. The aim of this review was to enable the clinician to know the indications and contra indications of distalization, timing of treatment, and to have a comprehensive view of the commonly used intraoral molar distalization appliances such as pendulum, distal jet, Keles slider, and first class appliance, in terms of designs, efficacy, and side effects. Clinician should be aware of the individual variations in treatment response with these appliances. The literature also recommends the avoidance of simultaneous bracketing while distalizing to ensure less reciprocal effects from distalization on anterior teeth such as proclination and increased over jet. Lately skeletal anchorage designs were introduced to overcome problems associated with non-compliance distalization appliances, which have also been reviewed and discussed in this paper.

Key words: Class II malocclusion, Distalization, intraoral distalizers, distal molar movement,

INTRODUCTION

One of the traditional approaches for molar Class II correction and space gaining is distalization, which could be obtained with either intraoral appliance (IOA) or extraoral appliance (EOA). The biggest advantage of IOA over EOA distalization is being not dependent on patient compliance but the distalization efficacy is not really evaluated between two methods, only one study by Brondemark and Karlsson 2005¹ based on randomized clinical trials compared cervical head gear with a force of 400g to 500g and used at least 12 hours with one IOA which is distalization by Nickel Titanium (NiTi) coils with a force of 180 gm to 200 gm, the study concluded that IOA was more effective than EOA to create distal movement of maxillary first molars; and that while moderate to acceptable anchorage loss was produced with IOA implying increased over jet. EOA created decreased over jet, but one should be aware that this anchorage loss in the IOA manifested by forward movement of 1 or 2 mm of the anterior and premolar teeth, in most instances, can be totally reversed and eliminated by subsequent multibracket appliance and intermaxillary class II elastics and it

would be even a favorable reciprocal effect in a case of retroclined upper incisors. Both appliances had negligible corrective effect on Class II Skeletal Relationship.²

For the clinician, the IOA is more favorable method than EOA to create distal molar movement as stated earlier. Much interest has been shown in appliances that depend minimally on patient cooperation.³

The IOA design includes two elements: the active components that distalize the maxillary molars and the anchorage unit that compensates for the reciprocally acting force system. The anchorage unit is a combination of dental anchorage and soft tissue rests or absolute different skeletal anchorage systems.³

Most of the studies are either case reports or small sample size studies that describes single individual appliances for its efficacy in distalizing upper molars and its side effects showed as molar tipping, mesialization of the anchorage components, with only few reviews that gather most of the distalizing appliance which could be utilized in the Clinic, Therefore, the aim of this Review is to enable the clinician to know

¹ Orthodontist, Dental Health Department, College of Applied Medical Science, Specialist Clinics / College of Dentistry/King Saud University

Correspondence: Dr. Lubna F. Al-Faleh, P.O.Box 91893, Riyadh 11643 – Saudi Arabia. Email: Lubna_dent@hotmail.com

most importantly the indications and contraindications of distalization, timing of treatment, and to have an overview of the common distalizing appliances including coil and wires, Intra oral bodily molar distalizer IBMD, Keles slider, Pendulum, Distal Jet, Jones Jig, First Class Appliance, Lokar Molar Distalizer, Beta-Titanium (TMA) Transpalatal bar appliance (TPA), with some highlights over the comparative studies of the most popular distalizers, ending with a review of the lately introduced skeletal anchorage systems used to overcome the side effects of both extraoral and intraoral distalizing appliances.

Timing of Distalization and second molar eruption

The influence of second molars on the distal movement of first Molars remains a matter of controversy; (Gianelly 1989, 1998)^{4,5} and Worms et al 1996⁶ stated that when the second molars are present, the treatment time predictably increases since there are 2 teeth to be moved distally and when the first molars are moved distally in the late mixed dentition stage, the procedure is 90% successful and molar correction can be completed within 4 to 8 months. Also Bussick and McNamara 2000⁷ noted in their study on pendulum appliance that distalization is always preferable before eruption of second molar because of minimal increase in lower facial height (LFH) at that stage. Bolla et al 2002⁸ stated that typical age for that treatment was 12-13 years, an age which corresponds to optimum amount of mandibular growth, which may also be useful in resolving the Class II relationship.

Another study by Kinzinger et al 2004⁹ evaluating the efficiency of pendulum appliance for molar distalization related to second molars and third molars eruption stage concluded that for young patients, the best time to start therapy with pendulum appliance is before the eruption of the second molars. If 2nd molars are present then more protrusion of incisors and Buccal drift of the 2nd molars must be accepted, although Bondemark 1998¹⁰ didn't identify any increase in transversal arch via distalization with magnates.

However, when it comes to distal tipping of distalized molars. Bolla et al 2002⁸ concluded that in patients treated with distal jet there is a greater tipping (4.3°) in subjects whose second molar is unerupted since the

center of the resistance moved from trifurcation to more superiorly, but didn't find any difference in mean distalization between patients with erupted or unerupted second molars. In contrast to distal tipping, it seems that anchorage loss is found to be significantly less (1.7mm vs. 0.9 mm) with less extrusion (1.7 mm vs. 0.5mm) measured at the first premolars for those subjects whose second molars were erupted as compared with those with unerupted second molars. Also noted by other workers (Chiu et al¹¹, Byloff and Darendeliler¹², Brickman et al¹³).

The effect of distalization on maxillary third molars is variable but in general no distal movement but 4° of tipping is observed (Papadopoulos et al 2004)¹⁴ and despite this lack of statistical significance, these positional changes of third molars can lead to impaction especially if there is no space available at the beginning of treatment.

In addition, third molars that have erupted or are close to erupting according to Gianelly 1998⁵ tend to impede the distal movement of 1st and 2nd molars. For this reason they are removed when possible.

Indications for Distalization

- Moderate maxillary skeletal and/or dentoalveolar protrusion.
- Moderate arch-length deficiencies.
- When extraction of the maxillary teeth is not indicated.
- The mandibular tooth-size/arch perimeter relationship does not permit mesial movement of the lower molars¹⁵.

Contraindication for Distalization:

Distalization should be avoided in the following conditions¹⁶⁻¹⁸:

- Full or protrusive profiles with severe incisors proclination
- High mandibular angles, and anterior open bites.
- Thin labial bone
- Deficient gingival height.

- Significant crowding (more than 6 mm)
- Ectopic canines.
- Patient with insufficient seating of the Nance button because of the reduced palatal vault inclination that would lead to insufficient anchorage.

Intra-arch Molar Distalizer Appliances

Compressed Springs

Although very common but little clinical trials had examined their effectiveness in Class II treatment. Gianelly 1998⁵ and Gulati et al¹⁹ advocated using this method in mixed dentition before eruption of second molars^{5,19,20}, and it was described using superelastic Ni Ti coils placed on a sectional wire of 0.016 x 0.022 stainless steel that extend from the first premolar to the first molar with either fixed or removable Nance appliance. When coils are activated about 10 mm it produces 100 grams of force, causing distalization on average of 1.5 mm/month with about 20% anchorage loss.

Yildiz et al²¹ concluded that in this method distal tipping of distalized molars was about 11°. 34° because of force being not on the level of the center of resistance, There was also about 9.75° of incisors proclination, with insignificant effects on mandible, therefore, it would be advantageous to use it in high angles cases

Jones Jig (compressed coil device)

Introduced by Jones and White 1992²² and it consists of a modified Nance appliance attached to the first premolars or primary 2nd molar with heavy round wire and a light wire projecting through molar tube, both wires are soldered to a fixed attachment sheath and hook, an open coil spring when activated delivers 70-75g of force, resulting in 1mm of anterior movement and in a range of 2.5mm to 2.8mm of molar Distalization². Treatment effects was also noted by Papdopoulos and Mavropoulos, 2004¹⁴ with a mean distal molar movement about (1.4mm), and increased overjet by (0.9mm) and overbite decreased by 1mm, with no significant changes in facial height.

One of the disadvantages of Jones Jig that should be in mind is the easy Breakage of the appliance. Fig (1)

Pendulum Appliance

Introduced by Hilgers, 1992¹⁵ and it consists of large acrylic Nance button that covers the midpoint of the palate, the acrylic pad connects to Upper first and second premolars by means of occlusal rests, the Nance button also serves as an attachment for two posteriorly extending Beta-Titanium (TMA) wire springs For distalizing Upper first molars. (Fig 2).

Due to anchorage consideration distalization is usually done one side at a time and about 5 mm of molar distalization can be seen in about 3-4 months. When palatal expansion is needed, screw is added and it is then called (Pendex).

A study carried out by Ghosh and Nanda,²³ concluded that 57% of space gained is molar distalization, 43% maxillary first premolars and anterior anchorage loss, 1.3mm increase in over jet with 2.8mm average increase in the lower anterior facial height. Another study by Joseph and Butchart, 2000¹⁶ noted significant distal tipping of first molar 15.7°, and, therefore, Byloff and Darendeliler¹² concluded that there is correlation between amount of distalization and increased molar tipping, so they added uprighting bends to the distalizing springs following distalization and found that it reduced the molar tipping.

First Class Appliance

The First Class Appliances (FCA) introduced by Fortini and his co-workers²⁴, can be used either unilateral or bilateral molar distalization. It consists of 4 bands, vestibular screws soldered to the single tubes and palatal Nance in butterfly shape, Open coil NiTi 10mm long is fully compressed between a solder joint on the anchor tooth and the first molar.

This device produces a rapid molar distalization on average of 4 mm in 2-4 months, with mean distal tipping of 4.6°. The maxillary central incisors proclined slightly during treatment (2.6°) with minimal increase in over jet (1.2mm) and no significant changes in sagittal or vertical skeletal relationship.

Intraoral Bodily Molar Distalizer (IBMD) (Compressed Coil Device)

The appliance was developed by Keles and Sayinsu (Istanbul, Turkey)²⁵, and consisted of maxillary first

molars and premolars bands. Wide acrylic Nance button for anchorage and deep bite correction is attached to the first premolar bands, and TMA springs oriented from the acrylic for Distalizing and Uprighting first molars.

The means of bodily distal movement of molars were 5.23mm. Incisors were protruded by 4.7mm and increased over jet of 4mm; Keles concluded that when we move the molars bodily, we get more anchorage loss.

During the stabilization period the premolar drifted distally and over jet was reduced spontaneously without any orthodontic therapy. Then Keles²⁰⁰¹²⁶ developed another intraoral appliance for unilateral distalization known as Keles Slider to overcome the side effects of the asymmetric head gear (Haack and Weinstein, 1958²⁷; Baldini 1980²⁸) which includes lateral forces that tend to move molars in to cross bite (Siatkowski's 1997²⁹, Yoshida et al 1998³⁰).

In Keles Slider (Figure 3) the point of distal force application was carried towards the level of centre of resistance of the maxillary first molar, utilizing Ni-Ti coil springs acting on the Class II molar. The advantage of Keles slider is less anchorage loss since half the whole contra-lateral side used as anchor unit, additionally, short chair side time and ease of reactivation. Keles Slider was modified in 2006³¹ with less acrylic palatal coverage and it showed more anchorage loss and less amount of molar distalization and It was concluded in this study that patients with palatally inclined or upright maxillary incisors should be selected for treatment with distalization devices. Later a study done on the biomechanics of keles slider 2008³² also concluded that deep bite patients should be indicated for this appliance after noticing extrusive forces combined with moderate buccal rotating moments at molars.

Distal Jet Appliance

Developed by Carano and Testa from Italy³³ (Figure 4), it is a palatal appliance that has many features in common with pendulum appliance but it has advantages that maxillary molars are distalized without palatal movement, the easily conversion to Nance appliance after distalization, and less molar tipping with more bodily movement since the design allows

force to be close to the center of resistance of first molars (McNamara and Brudon 2001)³⁴

When evaluating treatment effects, Bolla et al⁸, in his study, noted that 71% of the space is created by distal movement and 29% anchorage loss. They also noted variable amount of molar expansion (3.7 - 4.4mm) compared with other distalizing appliances which that has undesirable constriction at first molars as seen in pendulum, Jones Jig, Greenfiled appliances¹³.

The effects also were studied by Ngantung et al 2001¹⁷ and noted that molars are distalized by (2.1±1.8mm), tipped distally (3.3± 3.7°), over jet increased (about 1.7±3.8 mm) which may be attributed to the simultaneous use of full bracketing during distalization which was not recommended by Bolla et al 2002⁸, and there was no significant effect on LFH.

Deflection of Straight wires

Although, not as popular as compressed coil springs, compressed wires have also been adopted for molar distalization. Locatelli and colleagues³⁵ described the use of superelastic nickel titanium wires (Neosentalloy wires) to move molars distally (by placing crimpable stops mesial and distal to a compressed section of wire, causing 100 g distalization force against molars which is comparable to magnets and super elastic NI TI coils, Producing about 1-2 mm Distalization per month with little loss of anchorage.¹⁵

The Lokar Molar Distalizing appliance²:

It is an appliance that is inserted in to molar attachment with an appropriately sized rectangular wire, and a compression spring that is activated by a sliding sleeve [Figures 5 (a) and 5(b)]. This appliance is best used with Nance button but can be used without it if sufficient anterior anchorage exists. It can be used in mixed dentition or during complete edgewise treatment.

Advantages of this method includes:

- Extra oral force or lip bumper can be used
- Ease of activation and insertion
- Minimal breakage

Still there is no enough data regarding the effect of Lokar Distalizer on Molars and more studies are needed.

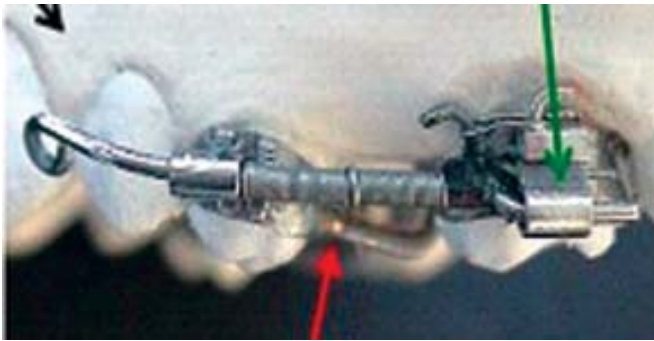


Fig 1: Jones jig distalizer

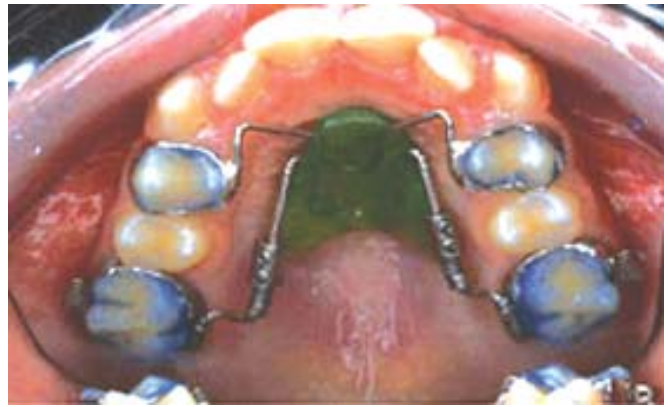

Fig 4: Distal jet appliance

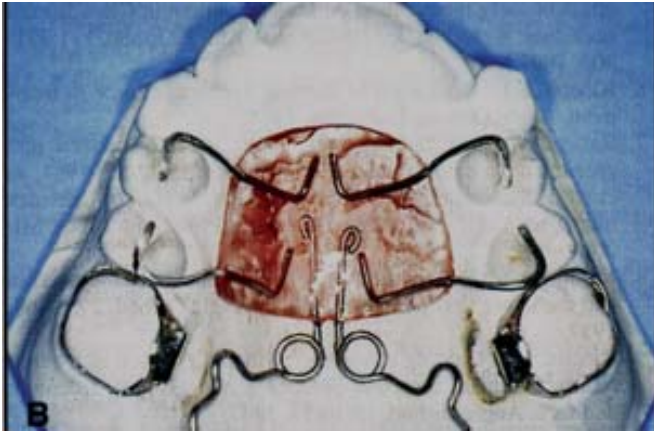

Fig 2: Pendulum appliance



Fig 5 : a. Lokar Distalizer

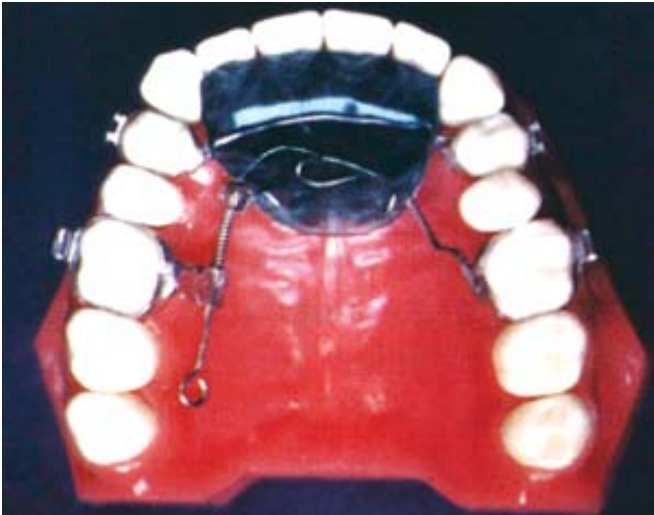

Fig 3: Keles slider



Fig 5 : b. Lokar Distalizer inserted to buccal segment.

Asymmetric Distalization with TMA TPA

In this method the molars are distalized with TPA made from TMA bars instead of stainless steel; the direction of insertion of TPA is made in a way that upon activation the arch applies a mesobuccal rotation to the anchor molars and a distally directed force to the opposite molar.³⁶ This TPA can be constructed by Lab

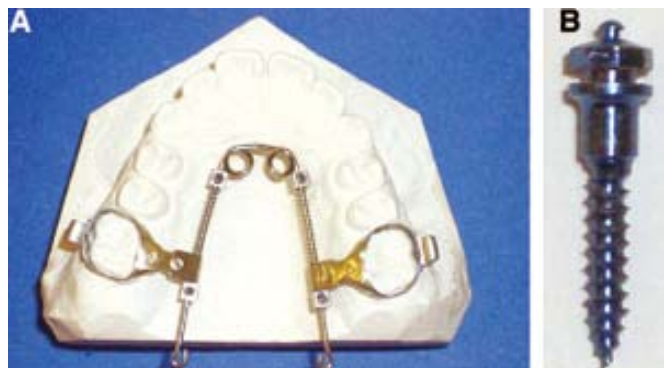

Fig 6: A, MISDS; B, the Aarhus miniscrew implant used with the MISDS.

or at office using Weingart pliers, and the Omega central loop is not needed.

Advantages include:

- Simple to construct.
- TMA has better shape memory
- No anterior anchorage loss

Comparison between different common intra-oral Distalizers

A study by Fortini et al²⁴ (Tables 1 and 2) compared distal jet, intraoral bodily molar distalizer and Jones Jig and first class appliance in terms of treatment duration, amount of distalization per months, molar tipping, anchorage loss, and concluded that the distal jet, intraoral bodily molar distalizer and first class appliances are shown to be the most efficient Intra-arch molar distalizers²⁴.

It is also noted from (Table 1 and 2) that no contemporary intra-arch molar distalizer provides completely effective anchorage loss control, which can vary from 24% to 55 % of the spaces created between the first molar and anchorage teeth. Therefore, Kinzinger & Diedrich 2008³ stated that recommendation of appliance efficiency can be given only to limited extent, since only few studies that evaluated treatment changes using cast analysis, not to mention that insight to other side effects such as adversely affected mucosa, can be found only rarely. Data on difficulties and problem of manufacture in the dental laboratory are lacking completely. In their study, they also concluded that Hilgers pendulum resulted in the longest dental-linear distalization measurements of all intraoral distalizers, with substantial undesirable distal tipping but by appliance modification that include Uprighting bends (Pendulum K) almost bodily molar distalization can be achieved with less tipping.

When comparing the coil spring designs, it would seem that the palatal distaljet and first-class appliance are more efficient in terms of distalization with less desirable side effects than the Vestibular Jones Jig (Kinzinger & Diedrich 2008³). Another recent study by Antonarakis and Kiliaridis³⁸ comparing the palatal coil designs with vestibular designs showed that Buccal acting and palatal acting appliances demonstrate almost similar results, with palatal acting appliances showing less tipping and appear to produce better

molar distalizing effects, but with a concomitant notable loss of anchorage. When comparing two Palatal appliances like distal jet to pendulum appliance, Bolla et al 2002⁸ compared both appliance and stated that net distalization was 3.2 mm per side compared to 5.7 mm as seen in pendulum, however less distal molar crown tipping (3.1 degree) is seen in the distal jet as compared to (10°) in pendulum appliance.

Another comparison study by Chiu et al 2005¹¹, which measured the anchorage loss that extended to the end of treatment, noted that despite more anchorage loss seen during treatment with distal jet, eventually both appliances had identical molar distalization (3mm) and therefore equally effective. They also concluded that simultaneous edgewise orthodontic treatment during molar distalization in distal jet shortened the overall treatment time, but produced significant flaring in both maxillary and mandibular incisors at the end of the treatment with distal jet compared to pendulum appliance.

Vertical Dento-Skeletal changes:

Distaljet, jones Jig showed a comparable results of extrusion (1.2mm molar extrusion, 1mm second premolars) while Gulati et al¹⁹ found that there is a greater increase in both molar extrusion and mandibular plane inclination in subjects treated with Jones Jig, and a greater increase in mandibular plane angle also has been reported for the pendulum appliance and intraoral bodily molar distalizer. However, a recent study by Kinzinger and Diedrich 2008³ stated that vertical aspects in relation to molar and premolars and incisors such as intrusion and extrusion, play only a minor part and may be ignored in terms of side effects.

Distalizers and Lower anterior Facial Height:

There are contrasting findings in the literature concerning that aspect, Ghosh and Nanda²³ noted after distalizing in patients with high, neutral and low pretreatment mandibular plane angles that the increase in the lower anterior facial height were greater in subjects with higher pretreatment mandibular plane angles. Another study with larger sample sized treated with FCA with range of low and high mandibular plane angles found no statistically significant differences in the inter-maxillary vertical relationship seen between groups but still it is always advisable to avoid

TABLE 1: COMPARISON OF EFFECTS OF MOLAR DISTALIZATION APPLIANCES

Report (reference)	Appliance	n rate	Distalization (mm/m0)	Distal tipping index (°/mm)	Anchor-age loss (%)	Molar distalization (%)	Achor-age loss (%)
Ghosh and Nanda 1996	Pendulum	41	0.5	2.5	0.7	57	43
Byloff and Darendeliler 1997	Pendulum	13	0.8	4.3	0.5	71	29
Byloff and Darendeliler 1997	Pendulum	20	0.6	1.5	0.5	64	36
Bussik and McNamara 2000	Pendulum	101	0.8	1.9	0.3	76	24
Chagues-Asensi and Kalra 2001	Pendulum	26	0.8	2.5	0.4	71	29
Gulati et al 1998	Jones Jig	10	0.9	1.3	0.4	71	29
Runge et al 1999	Jones Jig	13	0.3	1.8	1.0	50	50
Haydar and Uner 2000	Jones Jig	20	1.1	2.8	1.2	46	54
Brickman et al 2000	Jones Jig	72	0.4	3.0	0.8	55	45
Keles and Sayinsu 2000	IBMD	15	0.7	0.2	0.8	55	45
Ngantung et al 2001	Distal Jet	33	0.3	1.6	1.2	45	55
Bolla et al 2002	Distal Jet	20	0.6	1.0	0.4	71	29
Fortini et al 2004	FCA	17	1.7	1.1	0.4	70	30

This table is reproduced from the article written by (Fortini et al) referred at no. 24

TABLE 2: COMPARISON OF EFFECTS OF MOLAR DISTALIZATION APPLIANCES

Report (reference)	Appliance	N	Treatment duration (m0)	Molar distal movement (mm)	Molar distal tipping (°)	Pre-molar mesial movement (mm)	Pre-molar tipping (°)	Incisor vestibular movement (mm)	Incisor vestibular tipping (°)	Over jet (mm)
Ghosh and Nanda 1996	Pendulum	41	6.2	3.4	8.4	2.5	1.3		2.4	1.3
Byloff and Darendeliler 1997	Pendulum	13	4.1	3.4	14.5	1.6		0.7	1.7	
Byloff and Darendeliler 1997	Pendulum	20	6.8	4.1	6.1	2.2		1.0	3.2	
Bussik and McNamara 2000	Pendulum	101	7.0	5.7	10.6	1.8	1.5	1.4	3.6	0.8
Chagues-Asensi and Kalra 2001	Pendulum	26	6.5	5.3	13.1	2.2	4.8	2.1	5.1	1.8
Gulati et al 1998	Jones Jig	10	3.0	2.7	3.5	1.1	2.6			1.0
Runge et al 1999	Jones Jig	13	6.7	2.2	4.0	2.2	9.5		2.0	1.5
Haydar and Uner 2000	Jones Jig	20	2.5	2.8	7.8	3.3	6.0	0.2	1.0	
Brickman et al 2000	Jones Jig	72	6.3	2.5	7.5	2.0	4.8		2.4	-0.4
Keles and Sayinsu 2000	IBMD	15	7.5	5.2	1.1	4.3	-2.7	4.8	6.7	4.1
Ngantung et al 2001	Distal Jet	33	6.7	2.1	3.3	2.6	-4.3	12.1	1.7	
Bolla et al 2002	Distal Jet	20	5.0	3.2	3.1	1.3	-2.8	0.6	0.4	
Fortini et al 2004	FCA	17	2.4	4.0	4.6	1.7	2.2	1.2	2.6	1.2

This table is reproduced from the article written by (Fortini et al) referred at no. 24

IBMD = Intraoral bodily molar distalizer

*Positive value = mesial tipping; negative value = distal tipping

distalization for a very high mandibular plane angles with excessive lower facial height.²⁰

Profile changes with Distalization

Soft tissue effects was negligible until recently A comparative study of three different molar distalization appliance; the intraoral bodily molar distalizer, the Keles slider, and the acrylic cervical occipital appliance (ACCO) (ACCO is a combination of intraoral appliance and Cervical Head Gear) showed the most prominent soft tissue profile changes was seen with the intraoral bodily molar distalizer. The acrylic cervical occipital appliance and the Keles slider generated milder changes on the profile, as a result when selecting the appropriate method for maxillary molar distalization, the initial soft tissue profile should be considered.³⁸

Distalization of Maxillary Molars with palatal Implants and Miniscrew supported distalization system

Recently alternative anchorage designs using implants or miniscrews are described and the aim of these anchorage designs is to overcome the problems associated with the use of intraoral molar distalizers such as anterior anchorage loss expressed as forward movement and proclination of the anterior teeth, distal molar crown tipping during active distalization, and the forward direction that takes place during the subsequent stage of anterior tooth retraction.

Although absolute and supportive anchorage designs with palatal implants and miniscrews have been described a lot in the literature the principle differences can be found in the material and the type of application of the molar distalizing components such a Graz implant supported pendulum appliance (Byloff et al)³⁹, osseointegrated palatal implant instead of Nance button placed in the median palatine suture (Keles et al)⁴⁰ or distal jet in conjunction with a miniscrew anchorage system (Carano et al)⁴¹.

Beyza et al 2006 introduced the Bone-anchored pendulum appliance (BAPA)⁴², he and his co-workers evaluated the effectiveness of the appliance and showed a mean distalization of 6.4 mm, and Class I molar relationship was achieved in 7 months without any anchorage loss.

When comparing Conventional Orthodontic Implants (Wehrbein et al 1999, Roberts et al 1989, Keles

et al 2003,)⁴² to Miniscrews, the former had disadvantages in being complicated with invasive placement and removal surgical procedures, patient discomfort, high cost, and the fact that it can be only done by experienced oral and maxillofacial Surgeon, in addition to complex laboratory procedures for precise implant placement. Also the placement location are limited, and a waiting period for osseointegration before loading the implants with orthodontic forces is necessary which will eventually increase the treatment time⁴³.

In contrast to conventional anchorage implant, miniscrew implant are more widespread such as IMTEC Mini-implants (Herman and Cope 2005)⁴⁴ and spider screw (Maino et al 2005⁴⁵, 2007⁴⁶). The latter described an efficient method for class II non extraction treatment consisting of two phases, first distalization of the maxillary molars with superelastic coils and wire, and anchorage is provided by a transpalatal bar attached to the first premolars and ligated to 2 palatal miniscrews by steel ligature. Once the molars are positioned correctly, the palatal miniscrews are then removed and miniscrews are inserted bilaterally in the buccal bone between the first molar and the second premolar to serve as an anchorage for the retraction of the premolars, canines and incisors.

Papadopoulos 2008⁴³ illustrated a case using self-drilling Aarhus miniscrews in a system called implant supported distalization system (MISDS) for either unilateral or bilateral molar distalization, and recommended the paramedian palatal region for miniscrew placement due to the adequate bone support (specifically placed at a 4 mm distal and 3 mm lateral to the incisive foramen), These screws were not only used as an anchorage for the initial distal molar movement like the previous Maino et al protocol, but also for subsequent anterior tooth retraction, and since the same system is used for both molar distalization and anterior tooth retraction, He stated a safety clearance between the miniscrew implants and the roots of adjacent teeth of 7-10 mm which is significantly greater than the 2 mm considered the minimum prerequisite with miniscrew implants for anchorage⁴⁴ [Figure 6 (a & b)].

The treatment time lasted for 4 to 6 months depending on the severity, followed by stabilization period of 2 to 3 months for a spontaneous distal drift of all teeth anterior to molars; in phase II of treatment the same MISDS can be used as mentioned previously

for the subsequent anterior teeth retraction which could be carried out by stainless steel arch wires with contraction loops⁴³.

Despite the advantages of using skeletal anchorage in correction of Class II malocclusion complications of using them can still occur such as fracture, infection, instability of the miniscrew especially in thin cortex (thinner than 5 mm) and when the density of the trabecular bone is low, and root perforation due to inaccurate positioning.⁴⁷

In summary although Skeletal anchorage can overcome the unwanted side effects of intermaxillary noncompliance distalization appliances, future studies in larger samples are still needed to comparatively assess their efficiency, as well as studies to compare them with the conventional anchorage distalization methods.

CONCLUSIONS

- The noncompliance Intraoral molar distalization method has been a realistic compromise for patients who are unwilling to wear headgear.²³
- There is always a marked individual variation in patient response to these appliances in terms of anchorage loss and skeletal effects.¹⁴
- Anchorage loss can occur with almost all currently used intermaxillary appliances resulting in incisor proclination and increased over jet, which can be reversed in phase II multibracket treatment, Thus, it is advisable to delay bonding until the end of stabilization period when molars are uprighted.
- The reduced forces used for distalization has not proven to be effective as an anchorage loss deterrent, Hence, clinician must be prepared to add auxiliary forces such as HG or elastics when anchorage loss is more than 2 mm⁸.
- Pendulum resulted in the longest dental-linear distalization measurements, with substantial undesirable distal tipping. also when comparing buccal to palatal coil spring the later appear to produce better molar distalizing effects, but with a concomitant notable loss of anchorage³.

- Alternative anchorage designs using implants or miniscrews are described and the aim is to overcome the problems associated with the use of intraoral molar distalizers such as anterior anchorage loss, distal molar crown tipping. However, still future research is needed to comparatively assess their efficiency as well as studies to compare them with the conventional anchorage distalization methods.³

REFERENCES

- 1 Brondemark L, Karlsson I: Extraoral Vs Intraoral appliance for distal movement of maxillary first molars: A randomized controlled trial. *Angle Orthodontists* 2005; 75(5):699-701.
- 2 Devincenzo DJ: Treatment options for Sagittal Correction in non-compliant patients, *Orthodontics: Current Principles and Techniques* Book by Graber; 2008: 779-800.
- 3 Kinzinger GS, Eren M, Diedrich PR: Treatment effects of intraoral appliances with conventional anchorage designs for non-compliance maxillary molar distalization. A Literature review. *Euro J Orthod.* 2008; 30 (6):558-71.
- 4 Gianelly AA, Bednar J: Japanese NiTi coils used to move molars distally. *Am J Orthod. & Dentofacial Orthop.* 1989; 96:161-67.
- 5 Gianelly AA: Distal movement of the Maxillary Molars. *Am J Orthod. & Dentofacial Orthop.* 1998; 114:66-72.
- 6 Worms FW, Isacsen RJ, Speidel M: A concept and classification of centers of rotation and extraoral force systems. *Angle Orthod.* 1992; 14;246-72.
- 7 Bussick Tj, McNamra JA Jr.: Dentoalveolar and skeletal changes associated with the pendulum appliance. *Am j Orthod. & Dentofacial Orthop.* 2000; 117:333-43.
- 8 Bolla E, Muratore, F, Carano A, and Bowman S.J: Evaluation of maxillary molar distalization with the Distal jet: A comparison with other contemporary methods, *Angle Orthod.* 2002; 72:481-94.
- 9 Kinzinger GS, Fritz UB, Sander FG, Diedrich PR: Efficiency of pendulum appliance for molar distalization related to second and third molar eruption stage. *Am j Orthod & Dentofacial Orthop.* 2004; 125(1):8-23.
- 10 Bondemark L: A comparative analysis of distal maxillary molar movement produced by a new lingual intra-arch Ni- Ti coil appliance and a magnetic appliance. *Eur J Orthop.* 2000; 22(6): 683-95.
- 11 Chiu PP, McNamara JA, Franchi L: A comparison of two intraoral molar distalization appliances: Distal jet versus pendulum. *Am J Orthod. & Dentofacial Orthop.* 2005 ;128(3): 353-65.
- 12 Byloff Fk, Darendeliler MA: Distal molar movement using pendulum appliance part 1: Clinical and Radiological evaluation. *Angle Orthdo.* 1997; 67(4):249-60.
- 13 Brickman CD, Sinha PK, Nanda RS: Evaluation of the Jones Jig appliance for distal Molar movement. *Am j Orthod. & Dentofacial Orthop.* 2000; 118(5):526-34.
- 14 Papadopoulos MA, Mavropoulos A, Karamouzosa A: Cephalometric changes following simultaneous first and second

- maxillary molar distalization using non compliance intraoral appliance. *Am j Orthod. & Dentofacial Orthop* 2004; 65(2): 123-36.
- 15 Hilgers JJ: The pendulum and other molar distalizing appliances, *Orthodontics and Dendtofacial Orthop*. McNamara, 4th edition Chapter 20 pages 344-59.
 - 16 Joseph AA, Butchart CJ: An evaluation of the pendulum distalizing appliance *Semin Orthod*. 2000; 6(2):129-35.
 - 17 Ngantung V, Nanda RS, Bowman SJ: Posttreatment evaluation of the distal jet Appliance. *Am j Orthod. & Dentofacial Orthop* .2001; 120(2):178-85.
 - 18 Mavropoulos A, Sayinsu K, Allaf F, Kiliaridis S, Papadopoulos MA, Keles A. Non compliance unilateral maxillary molar distalization: A three dimensional tooth movement analysis. *Angle Orthod* 2006; 76(3):382-87.
 - 19 Gulati S, Kharbanda OP, Parkash H: Dental and skeletal Changes after intraoral molar distalization with sectional Jig Assembly. *Am j Orthod. & Dentofacial Orthop* 1998; 114(3): 319-27.
 - 20 Keim R, Berkman C: Intra-arch maxillary molar distalization Appliance for Cl II correction, *JCO* 2004; 38(9):505-11.
 - 21 Yildiz O, Firatli S, Levent A: An evaluation of intraoral molar distalization with Nickel-Titanium coil springs; *Quintessence Int*.2005; 36;731-35.
 - 22 Jones RD, White JM: Rapid class II molar correction with an open-coil jig, *J Clin Orthod*; 1992; 26: 661-64.
 - 23 Ghosh J, Nanda RS: Evaluation of an intraoral maxillary molar distalization technique. *Am j Orthod. & Dentofacial Orthop*. 1996; 110: 639-46.
 - 24 Fortini A, Lupeli M, Guintali F, Franchi L: Dentoskeletal effects induced by rapid molar distalization with the first class appliance. *Am j Orthod. & Dentofacial Ortho*. 2004; 125 (6):697-705.
 - 25 Keles A, Sayinsu K: A new Approach in maxillary molar distalization: intraoral bodily molar distalizer. *Am j Orthod. & Dentofacial Orthop*. 2000; 117(1): 39-48.
 - 26 Keles A. Maxillary unilateral molar distalization with sliding mechanics: a preliminary investigation. *Euro J Orthod*. 2001; 23:507-15.
 - 27 Haack DC, Weinstein S: The mechanics of centric and exentric cervical traction. *Am J Orthod*. 1958; 44: 346-47.
 - 28 Baldini G. Unilateral headgear: lateral forces as unavoidable side effects. *Am J Orthod*. 1980; 77: 333-40.
 - 29 Siatkowski RE: Asymmetric headgear. In: Nanda E (Ed) *Biomechanics in orthodontics*. W.B. Saunders, Philadelphia, p. 130.
 - 30 Yoshida N, Jost-Brinkmann PG, Miethke RR, König M. Yamada Y: An experimental evaluation of effects and side effects of asymmetric face-bows in the light of *in vivo* measurements of initial tooth movements. *Am j Orthod. & Dentofacial Orthop*. 1998; 113: 558-66.
 - 31 Sayinsu K, Isik F, Allaf F, Arun T. Unilateral molar with a modified slider, *Eur J Orthod*. 2006; 28(4): 361-65.
 - 32 Kinzinger G and Diedrich P: Biomechanics of the Keles Slider Appliance for Maxillary Molar Distalization – *in-vitro* Analysis of Force Systems: *J Orofac Orthop*. 2008; 69(5):365-72.
 - 33 Carano A, Testa M: The distal jet for upper molar distalization. *J Clin. Orthdo*. 1996; 30(7):374-80.
 - 34 McNamera JA and Brudon WL: Orthodontics and Dentofacial Orthopedics. *J Cranio Maxilofacial Surg* 2003; 31:262-63.
 - 35 Locatelli R, Bednar J, Dietz VS, Gianelly AA. Molar distalization with superelastic NiTi wire. *J Clin Orthod*. 1992; 26:277-79.
 - 36 Mandurino M, Baducci I: Asymmetric distalization with a TMA transpalatal Arch, *J Clin Orthop*, 2001; 35(3):174-78.
 - 37 Antonarakis GS, Kiliaridis S: Maxillary molar distalization with noncompliance intramaxillary appliances in class II malocclusion. A systematic review: *Angle Orthod*. 2008; 78 (6):1133-40.
 - 38 Sayinsu K, Isik F, Ulqen AN: A comparative study of profile changes with 3 different distalization mechanics. *World J Orthod*. 2007; 8(1): 37-44.
 - 39 Byloff FK, Karcher H, Clar E, Stoff F: An implant to eliminate anchorage loss during molar distalization: a case report involving the Graz implant-supported pendulum. *Int J Adult Orthod Orthognathi Surg* 2000;15:129-37
 - 40 Keles A, Erverdi N, Sezen S. Bodily Distalization of molars with Absolute anchorage. *Angle Ortho* 2003;73:471-82.
 - 41 Carano A, Velo S, Leone P, Siciliani G. Clinical applications of the miniscrew anchorage system. *J Clin orthod*.2005;39:9-24
 - 42 Beyza HK, Zafer OP, Cem Kircelli, Maxillary Molar distalization with a Bone-Anchored pendulum Appliance, *Angle orthodontist vol 76*, 2006; 650-659
 - 43 Papadopoulos MA. : ortho. Treatment of Cl II malocclusion with miniscrew implants, *Am J orthod Dentofacial orthop* 2008; 134:604:1-16
 - 44 Herman R, cope Jb , miniscrew implants: IMTEC mini ortho implants .*Semin orthod* 2005 ;11:32-39
 - 45 Maino BG, Mura P, Bednar J. Miniscrew implants: the spiderscrew anchorage system. *Semin Orthod* 2005;11:40-46.
 - 46 Maino BG, Gianelly AA, Bednar J, Mura P, Maino G. MGBM system: new protocol for Class II non extraction treatment without cooperation *Prog Orthod* 2007;8(1):130-43.
 - 47 Melsen B . Mini – implants where are we? *J Clin orthdo* 2005;39: 539-44