

ORTHODONTIC UPRIGHTING OF IMPACTED MANDIBULAR PERMANENT SECOND MOLAR — A CASE REPORT

¹HAMEEDULLAH JAN, BDS, MCPS, FCPS
²ASIF KHURSHID, BDS, FCPS, Part II Resident
²AMJAD NAEEM, BDS, FCPS, Part II Resident

ABSTRACT

Due to the change in the life style and eating habits, impactions of teeth are on the increase. Mandibular 3rd molars and at times second molars are not the exceptions. They pose not only a big challenge to an oral surgeon but also provides a golden opportunity to the treating orthodontist by leveling and aligning it, thus enabling the dental occlusion to become stabilized and integrated in a much more balanced and harmonized manner.

Mandibular second molar plays a major role not only in function but also as a reinforcing anchor in orthodontics. Its significance is of paramount importance. Maximum efforts are to be exercised in saving and conserving this tooth in the oral cavity. Oral surgery should be the last resort in the treatment modalities. It should be undertaken only, when the orthodontic treatment fails due to the difficult spatial relationship of the tooth and is jeopardizing survival of the vital neighboring anatomical structures.

A case report of a young girl with mesioangularly impacted left second mandibular molar is presented. Both 1st and 3rd molars of the ipsilateral side were present and fully erupted. The impacted tooth was managed orthodontically and no surgical intervention was resorted to minimize invasive procedures.

Key words: Mandibular second molar, Impaction, Molar uprighting

INTRODUCTION

Impaction of permanent teeth is a common clinical occurrence and may involve any tooth in the dental arch. The teeth impacted in order of frequency are mandibular and maxillary third molars, maxillary canine and mandibular second premolar. Incidence of mandibular second molar impaction is less and estimated to be about 0.03 to 0.04% of all impacted teeth.¹ Mandibular second molar impaction is very challenging for both orthodontists and oral surgeons. Common age of presentation is 11 to 13 years.² The etiology of impaction is related to some disturbances of physiological mandibular growth and tooth development, arch length deficiency and distanced developing second molar and first molar.³ The most important iatrogenic factors include incorrectly fitted band on first mandibular molar, previous orthodontic distalization of 1st molars and prevention of mesial shift of first molar orthodontically.⁴ Uprighting of mandibular permanent second molar should establish normal functional occlusal relationship without any associated periodontal,

periapical and restorative pathology. Advantages of impacted molar uprighting are functional, periodontal, restorative and avoidance of shortening of occlusal table.³ A case report of young girl having impacted 2nd molar along with the presence of 1st and 3rd molar on ipsilateral side, who have been managed purely on orthodontic grounds without any intervention of an invasive surgical procedure is presented.

CASE REPORT

A 20-year-old girl visited the orthodontic department of Armed Forces Institute of Dentistry (AFID) with the chief complaint of unaesthetic appearance of prominent upper front teeth (Fig 1). After taking the relevant history, patient was examined clinically. On intraoral examination patient had fully erupted permanent dentition except mandibular left permanent second molar. A diagnostic panoramic radiograph revealed that mandibular left second molar was tipped mesially and was mesioangularly impacted under the distal proximal surface of permanent first molar

¹ Colonel Hameed ullah Jan, Associate Professor of Orthodontics, Armed Forces Institute of Dentistry, Rawalpindi. Email: huj100@hotmail.com

² Resident in Orthodontics, Armed Forces Institute of Dentistry, Rawalpindi

Correspondence: Dr. Asif Khurshid, Department of Orthodontics, AFID, Rawalpindi. Contact No: 0332 5002052, Email: drasif_79@yahoo.com

(Fig 2). Mandibular third molar on that side was developing normally with more than half of the roots formed. The orthodontic treatment including uprighting

of # 37 and bring it to normal occlusal table was customized. Space development was using standard preadjusted edgewise bracket system. The push coil



Fig 1: Pre-treatment frontal view

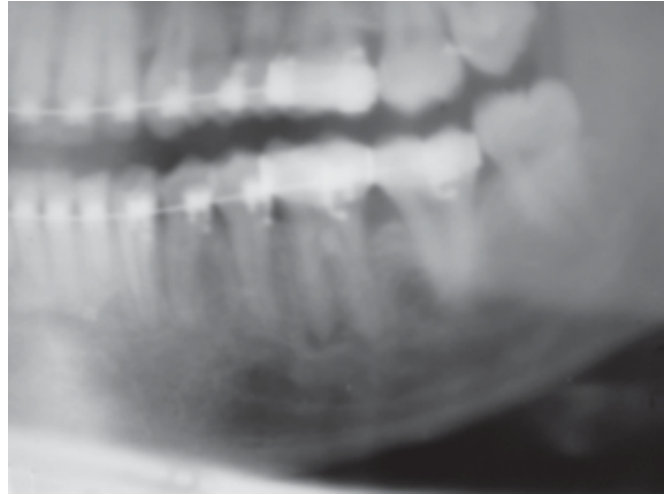


Fig 4: Panoramic view of upright molar

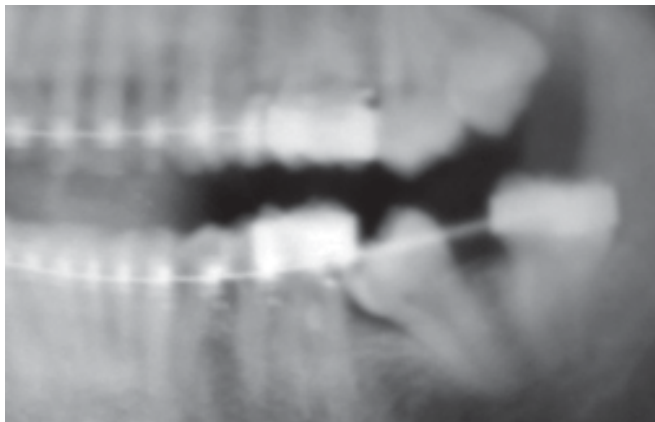


Fig 2: Pre-treatment Panoramic view

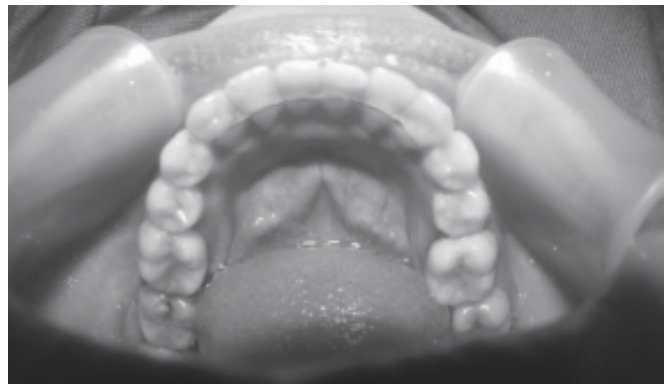

Fig 5: Post-treatment Fixed Retainer

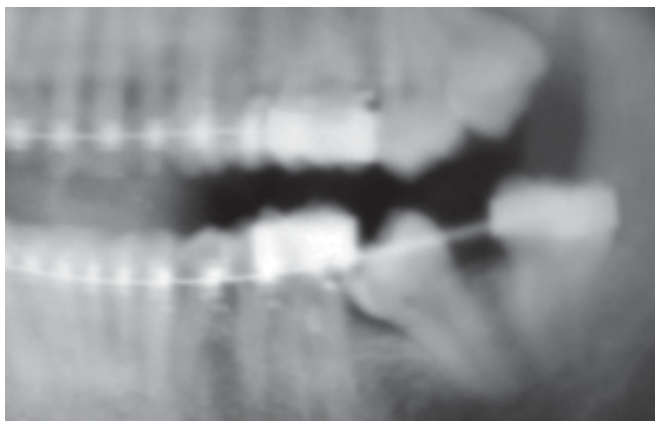


Fig 3: Intra treatment panoramic view



Fig 6: Post-treatment frontal view

spring of 0.010"x0.030" was used. All first molars as well as mandibular left third molar were banded with stainless steel band having pre-welded buccal tubes.

TREATMENT OBJECTIVES

Our first goal was to improve patient's overall dentofacial esthetics and complete restoration of a balanced and functional occlusion in a healthy oral hygiene environment. The foremost objective in this regard was to control dental discrepancies like proclined maxillary incisors, labioversed mandibular canines and level the arches before resolution of the impacted mandibular second molar.

TREATMENT ALTERNATIVES

- 1 Addressing the chief complaint, i.e., unaesthetic anterior teeth and leaving the impaction unresolved.
- 2 Orthodontic treatment of patient's chief complaint regarding comprehensive orthodontic treatment and concomitant with the solo surgical intervention for the facilitation of uprighting and eruption of mandibular second molar.^{5,6}
- 3 Uprighting and facilitating the eruption of impacted mandibular second molar solo orthodontically, using fixed orthodontic treatment by creating space and banding the mandibular left third molar as well.
- 4 Surgical extraction of second molar with mesialization of third molar achieved through comprehensive orthodontic therapy.⁵

Out of the above mentioned treatment alternatives the patient opted for non surgical management with resolution of the impaction through fixed orthodontics mechanics only.

TREATMENT PROGRESS

The patient received scrupulous oral hygiene instructions. The level of motivation was assessed over the next few appointments.

Once patient's overall oral hygiene status got improved and patient was found much more motivated for orthodontic treatment. Comprehensive treatment was commenced with.

We banded all first molars initially, with bonding of the teeth. We used 0.022" slot Roth appliance. Initially 0.014 NiTi wires were placed.

The mandibular left third molar was banded at a subsequent appointment. The wires were progressively changed to 0.016 and 0.018 NiTi as alignment improved before placing stainless steel wires.

When we achieved an adequate degree of alignment we progressed to 0.017" x 0.025" stainless steel wires in both arches. It was at this point that an active push open coil spring was placed between the lower left third and first molars. By doing this our objective was to create space for the impacted second molar.

After two subsequent activations, the second molar showed spontaneous deimpaction and it was accessible to banding (Fig 3).

The second mandibular molar was separated and banded. Light NiTi wires were reengaged and the molar aligned uneventfully (Fig 4).

Finishing wires were placed and final intercuspation was achieved through use of inter-arch elastics.

We gave her fixed retainers bonded to the six anterior teeth (Fig 5). This retention plan was executed and was deemed necessary because of the pretreatment mild rotation found in mandibular canines.

DISCUSSION

There is little literature available regarding mesially impacted second molar. Inadequate arch length is the principle cause of impactions; other causes include excessive distance between developing second and first molar resulting in mesial inclination of the second molar beneath the first.^{1,7}

Delayed emergence of second premolar, premature extraction of primary second molar, ankylosed primary molars, dentigerous cysts, competition for space by third molars and odontomes are some other factors blamed for second molar impactions.⁶ Inappropriately fitted bands on the first permanent molar can cause hindrance of eruption of second molars resulting in mesial inclination and eventually, the impaction of second permanent molars³.

Despite so many factors playing a role, sometimes unknown factors result in impaction of second molars, unilaterally while the contra lateral erupts normally.¹

The proper timing of treatment for such impactions is when the patient is about 11 to 14 years of age, when the root formation is incomplete.³ But in our case, the patient reported at the age of 20 years with complete root development.

Various orthodontic techniques have been employed in literature. If there is slight contact between the first and second molars then separators can be placed to relieve the tight contacts. This results in separation and resolution of the impaction spontaneously.⁸

In case of a deeper location of the impaction beneath the contact point of the first molar more

comprehensive management is required. Modalities include bonding attachment to disto-buccal surface,⁶ fixed in vertical lingual sheath, push open coil springs, inter-arch vertical elastics², pin placement in the crown of impacted second molars and use of auxiliary springs. Bonded tubes on the buccal surface with uprighting springs or super-elastic NiTi^{4,9}, tip back uprighting³ and helical uprighting spring¹⁰ can be used.

In our case we have used push open coil spring with the conventional fully adjusted edge-wise appliance. The significant advantage of using this technique is distal tipping and uprighting of the impacted tooth without surgical intervention.

Another added and significant advantage of our technique is that we avoid wire bending and bulk springs that can irritate the buccal mucosa and cause discomfort to the patient.

Management of severely impacted teeth with surgical repositioning is a quick option where orthodontic treatment is not considered a viable option.¹⁰ Disadvantages of this procedure include loss of tooth vitality, root resorption, ankylosis and periodontal problems.^{1,7,11}

In cases where the impaction is unsalvageable, removal followed by mesialization of the third molar, orthodontically can be considered.^{7,12} A drawback of this modality includes the long time span between the eruption times of these two teeth and unpredictability of third molar eruption.¹

Unresolved impactions have deleterious effects like, root resorption, caries and even periodontal breakdown of the first molar. Pulp necrosis and ankylosis of the first molar has also been reported.

In every case it is recommended that third molar status should be evaluated and tailored on individual basis. The decision of salvage or extraction should be vividly based on clinical requirements as in our case, the third molar was erupting normally and it was used strategically for anchorage purpose.

CONCLUSIONS AND RECOMMENDATIONS

With the advent of modern orthodontics, many hardships and hurdles in dentistry have been overcome by a prudent orthodontist. Impactions once deemed too difficult to handle have become much easier today than ever before.

To avoid dental phobia and to act upon the principal of minimal invasive dentistry, surgical option should only come into play once all orthodontic modalities of treatment fail and no other option is left to the clinician.

An impacted and/or ectopically placed tooth is an important dental unit rather a dental capital without which integrity and compliment of teeth will never be existing.

All clinical efforts and maximum orthodontic strategies are to be adapted in handling this type of challenging situation.

Adding this impacted tooth to the dental arch will boost up, not only the integrity of the arch but will also help in restoring a more balanced and harmonized functional occlusion.

REFERENCES

- 1 Shapira Y, Borell G, Nahlieli O, Kuflinec MM. Uprighting mesially impacted mandibular permanent second molars. *Angle Orthod.* 1998; 68: 173–8.
- 2 Reddy SK, Uloopi KS, Vinay C, Subba Reddy W. Orthodontic uprighting of impacted mandibular permanent second molar. *J Indian Soc Pedod Prev Dent* 2008; 26: 29-31.
- 3 Sawicka M, Racka-pilszak B, Mazurkiewicz RA. Uprighting partially impacted permanent second molar. *Angle Orthod* 2007; 77:148-58.
- 4 Eckhart JE. Orthodontic uprighting of horizontally impacted mandibular second molars. *J Clin Orthod* 1998; 32: 621–4.
- 5 Frank C. Treatment options for impacted teeth. *J Am Dent Assoc* 2000; 131:623-32.
- 6 Pogrel MA. The surgical uprighting of mandibular second molars. *Am J Orthod Dentofacial Orthop* 1995; 108: 180–3.
- 7 McAboy CP, Grumet JT, Siegel EB, Iacopino AM. Surgical uprighting and repositioning of severely impacted mandibular second molars. *J Am Dent Assoc* 2003; 134: 1459–62.
- 8 Moro N, Murakami T, Tanaka T, Ohto C. Uprighting of impacted third molars using brass ligature wire. *Aust Orthod J.* 2002; 18:35–8.
- 9 Aksoy A, Aras S. Use of nickel titanium coil spring for partially impacted second molars. *J Clin Orthod.* 1998; 32:479–82.
- 10 Shellhart CW. Uprighting molar without extrusion. *J Am Dent Assoc* 1999; 130:381-5.
- 11 Diedrich PR. Orthodontic procedures improving periodontal prognosis. *Dent Clin North Am* 1996; 40: 875-87
- 12 Yehoshua S, Borell G, Nahlieli O, Kuflinec M, Stom D. Second molar impactions. *Angle Orthod* 1999; 68:173-8.